



Liposuction Techniques

Dennis J. Hurwitz

Summary

Liposuction treats lipodystrophy and reduces the thickness of body contouring flaps. Patients are evaluated for suitability of deformity, skin quality, and understanding of the procedure. Inelastic and hanging skin is contraindicated for aesthetic lipoplasty. In general, a circumferential approach is taken to maximize skin shrinkage and harmonize the result. The traditional technique of suction-assisted lipectomy is presented with emphasis on smoothing and delivering the fat by the helping hand. Large-volume liposuction requires attention to maintain normothermia, fluid balance, and deep vein thrombosis (DVT) prophylaxis. Of the special energy sources, power assisted, laser, and ultrasonic, the author prefers and elaborates on ultrasonic and radio-frequency usage. By reducing, undermining, and gentle fat removal, liposuction can safely and effectively be combined with extensive body contouring surgery.

Abbreviations

IPC	Intermittent pneumatic compression
LVL	Large-volume liposuction
PAL	Power-assisted lipoplasty
SAL	Suction-assisted lipectomy
UAL	Ultrasonic-assisted lipoplasty
RFAL	Radio-frequency-Assisted lipoplasty

Introduction

Liposuction is aspiration of fat from the subcutaneous tissue. Liposuction can be applied to aesthetic lipoplasty or combined with body contouring surgery. Aesthetic lipoplasty is commonly called suction-assisted lipectomy (SAL). Blunt-tipped cannula, high-vacuum method of SAL was introduced in the United States from Europe and was rapidly embraced during the 1980s.²² SAL is repeatedly surveyed as the most common aesthetic procedure performed by plastic surgeons.⁴ Liposuction treats lipodystrophy, which is characterized by gender-specific deforming accumulations of fat. Men tend to seek reduction of gynecomastia, flank, and central abdominal fat. Women desire removal of fat from the central neck, lateral to the breasts, through the mid torso, along the hips, lateral thighs, inner thighs, and knees.

Liposuction is a closed technique that applies destructive energy to the subcutaneous tissue followed by aspiration of the emulsion. The usual energy is high-pressure vacuum pulling and avulsing fat through side openings in a hollow cannula. Alternative energy systems are power-assisted, laser-assisted, ultrasonic-assisted lipoplasty and radio-frequency-assisted.

Evaluation of the Patient

Ideal candidates for SAL complain of localized bulges of fat. They are young, healthy, and



of normal weight, with good skin turgor and understand the objectives, risks, and postoperative management of their planned treatment. In most areas, hundreds of cc's of fat emulsion can be removed, and normal skin retracts to the smaller volume. Commonly successful locations are the male breasts, hips, lateral thighs, medial thighs, and knees. Nearly as predictable are the neck, flanks, back, abdomen, and upper arms. Prolonged swelling, contour irregularities, and inadequate results limit procedures in the calf and ankle.⁴³

To avoid looseness or sagging, the skin needs to be elastic, and that determination is based on observation and palpation. There are some physical signs that predict diminished elastic recoil— a dense pattern of striae or stretch marks due to fractured dermal elastin subsequent to pregnancy, prolonged use of steroids, or rapid increase in size portends poorly for contractility after fat removal. Doughy skin is soft with poor tone and does not contract. The puckering of cellulite is indicative of disordered adipose architecture, which may be further distorted after liposuction. Excessively mobile and sagging skin is a contraindication for SAL.

A few patients describe a local area of contour bulge, and after proper evaluation, it may be treated in isolation. Most patients presenting for body sculpturing through liposuction have a three-dimensional deformity. The plastic surgeon must appreciate idealized gender-specific contours and be able to imagine them on his/her patient to plan the fat removal. Both the focal areas of concern and the adjacent areas need treatment. The focal areas are blended into each other, generally requiring a circumferential approach.

Candidates for localized reduction have limited excess fat with adequate tone and minimal striae. Localized suctioning is most suitable in the abdomen. Care must be taken to rule out epigastric bulges due to visceral adiposity and/or myofascial weakness. Extension of the fat removal through the enlarged flanks is often advantageous but can be of limited benefit in the apple-shaped torso.

Circumferential Liposuction and Planning

When contour deformity of the lower extremities is being treated, one considers circumferential

liposuction, which means that the suctioning of one area of fullness is continuously blended into another. Circumferential liposuction enhances skin shrinkage. The author believes that this happens because the less vigorously treated blended zones undergo far less trauma from the liposuction. With only minimal fat removed, the connective tissue is better preserved, leading to maximal contractility. The fully suctioned bulging areas sustain greater damage to the connective tissue, which limits contraction. It is commonly accepted that superficial lipoplasty immediately under the skin assists in skin contraction. Unfortunately, this approach risks devascularization of the skin, which leads to skin necrosis. Therefore, most plastic surgeons are reluctant to take maximal advantage of superficial lipoplasty. Finally, injury to connective tissue may lead to scar formation, with resulting shortening of collagen bundles, leading to dermal skin retraction. Excessive scarring leaves the skin firm and wrinkled.

The patient stands for preoperative liposuction planning. Bulging areas are observed, palpated, and lightly stroked and pinched to map out removal. The focal area is outlined, and the magnitude of excess fat is indicated by plus marks ranging from + to+++ . Skin quality is considered. Depression areas are indicated by minus marks. Lipoaugmentation may be performed for some fill in those areas. Markings are circumferential with one focal zone blending into another. There are recognized zones of adherence about the lower lateral and lower posterior thigh. It is exceptional that much needs to be removed in those regions.

Examine for symmetry and overall contour. Estimate the volume of removal to guide fluid infusion and need for hospitalization. A simple aid to estimating volume is to multiply place a 60 cc syringe in the area of planned liposuction and count the number of syringes that would be filled by the excess volume and multiply by 60. Generally, 1 cc of fluid is infused for every cubic centimeter of anticipated fat removal. Over 5,000 cc of removal prompts overnight in-hospital monitoring.²⁴ Patient positioning is considered. For most procedures, the patient lies supine and is turned from side to side. If considerable fat is to be removed from the back, the operation is begun while the patient lies in the prone position. Several access sites are chosen for each area. There are a variety of cannulas, aspirators, and energy-assist systems.



The surgeon's experience and judgment far outweigh the advantages of a particular tool. I suggest continuing trials with new equipment with purported improved features.

SAL Technique

As a blind procedure, SAL relies on tactile feedback, observation of the effluent, and contour change. As much as possible, the surgeon's dominant hand infuses the preparatory fluid, directs the energy-tipped probe, and aspirates the fat. The helping hand is flattened as it detects the progressive thickening of the infusing fluid through the layers of subcutaneous tissue. During liposuction, the hand smoothes and firmly compresses the target area to expedite the fat removal and sense the depth of delivery. Greatest compression is over the multiple plus areas or when the fat does not evacuate easily. Grasping the tissue, forming a cylinder and suctioning within the hand are discouraged as that method leads to ridging or depression.

SAL begins with infusion of saline containing xylocaine with epinephrine into the target subcutaneous tissues until a palpable firmness is attained. One ampule (1 mg) of epinephrine and 20 ml of 1% xylocaine plus sodium bicarbonate 10% by volume are added per liter.²⁸ A thin, multiple-holed, reusable, blunt-tipped needle is connected to the infusion tubing and pump that delivers fluids under desired speeds. Infusion speed, up to 450 cc/min, increases with the anticipated volume of aspirate and the thickness and firmness of the tissues. Through even diffuse infiltration of fluid, the target is enlarged, anesthetized, and vasoconstricted, making the aspiration easier, more even, and virtually bloodless. The operation starts with larger cannulas (diameters between 4 and 5 mm) with multiple holes to speed the evacuation of deeper layers of subcutaneous fat. One area is incompletely treated before advancing to a contiguous one. Then a return is made to the previous area to allow for controlled progressive reduction in volume, all the while continuously assessing the reduced thickness and evenness of the subcutaneous layer with the helping hand. Smaller cannulas (diameters between 2 and 4 mm) follow for even removal of subdermal fat and persistent bulges. When nearing the completion of liposuction, two-handed pinch and spreading evaluation is

needed. Crisscross suctioning further smoothes out areas. Minor lumpiness can be corrected by firm message with a pizza type roller. For large-volume fat removal, multiple holes increase the evacuation of fat, especially when they are staggered. A 5 mm in diameter, 20 offset holed cannula is a remarkably rapid aspirator, particularly in fibrous tissue.

Fat removal in the extremities is primarily through long longitudinal strokes, supplemented with secondary shorter, roughly perpendicular strokes through staggered access incisions. The main access incisions of the upper arm are made around the elbow and the Deltopectoral groove. Incisions of the hip and lateral thighs are made along the mid lateral line. Refinement of the contour is mainly transversely oriented with smaller cannulas moved rapidly in a radial manner. Stay deep in the lateral thigh. Frequently assess the contour to avoid over-resection. Transversely oriented excessive liposuction leads to unsightly transverse depressions, which are most noticeable when standing. Multiple access sites allow for better blending of areas in a circumferential effort.

Medical Management

Circumferential liposuction takes longer than focal liposuction, with considerable exposure of the body, usually with position changes and larger volume removal. Greater quantities of aspirate simply magnify the safety considerations. Large-volume liposuction (LVL) aspirates over 5,000 cc.²⁴ Consideration must be given to avoiding intraoperative hypothermia, appropriate fluid resuscitation, and deep vein thrombosis (DVT) prophylaxis³⁰.

Hypothermia

Although profound hypothermia with its attendant cardiac and coagulation instability is rare, only a few degrees centigrade drop may lead to wound infections if combined with excisional surgery.⁴⁵ Force hot air warming, warmed fluids, and warmed room are recommended. Force hot air warming of the patient in the preoperative area may be advantageous but may be difficult to organize. If the marking is performed immediately preoperatively, expect the patient to be chilled and consider a 15-min warmup period before the induction of anesthesia.



Fluids

Intravenous fluid management relates to the magnitude of subcutaneous fluid infusion for the liposuction. Fluid shifts in LVL can be quite dramatic, leading to either hypovolemia or fluid overload, necessitating in-hospital management until stable.^{27,41} Overload leading to congestive heart failure or pulmonary edema is at greater risk for the larger volume aspirates since between 60% and 80% of the infiltrating wetting solution remains in the subcutaneous tissue until slowly absorbed or drained by closed suction. In addition to maintenance fluids, intraoperative replacement fluid is 0.25s cc crystalloid for each 1 cc of aspirate over 5,000 cc. A simplified and effective method of managing intraoperative fluids is to maintain a fluid ratio of 1 and a urine output of 1–1.5 ml/kg/h. The intraoperative fluid ratio is defined as tumescent fluid volume plus intraoperative replacement divided by the volume of the aspirate.^{41,42} Since there is no linear correlation between the postoperative drop in hemoglobin level and the volume aspirate, measured hemoglobin levels and clinical judgment should be used.²⁵ Postoperative fluid maintenance should probably be less than 2 cc/kg/h with adjustments based on urine output, vital signs, and condition of the patient.

Xylocaine and Epinephrine

At about 30 ml of 1% xylocaine per liter of infusate, the analgesic effect is adequate with minimal sedation. The role of infusate xylocaine under general anesthesia is questioned because of toxicity.²⁶ Obviously, the risk of xylocaine toxicity is completely avoided by omitting it from the infiltration solution. The analgesic effect lasts less than 8 h, even though xylocaine and its active metabolic byproducts last up to 28 h. Patients appreciate the virtually pain-free emergence from anesthesia after major body contouring surgery; xylocaine is used in the first 3,000 cc and then reduced in further infusions.⁴¹

At 1 mg/l epinephrine infusion, plasma epinephrine levels may increase 3–4 times above baseline during liposuction, with peak concentrations around 300 pg/ml reached between 1 and 4 h after infiltration began.⁶ Approximately 30%

of the infiltrated epinephrine is absorbed, with no clinical signs of toxicity such as anxiety, restless, weakness, pallor, tremor, heart palpitations, and/or vomiting.

All patients are started on an intermittent pneumatic compression (IPC) device immediately before surgery and are continued throughout the hospitalization and until regularly ambulating. Low-dose, low molecular weight heparin is considered until ambulating in patients with multiple risk factors.³⁹

Postoperative Care

After a compulsive effort is made to smooth out irregularities, the small incisions are loosely closed with 3–0 nylon sutures. Tightly fitting, encompassing, commercially available elastic garments support the operative areas. Along the extremities, circumferential compression encourages drainage and retards swelling. The expected drainage is allowed to leak out of the access incisions through the garment. Drains may be used in the thighs when large volumes are removed. There may be no practical means to immediately compress the larger thighs and that may await custom fitting some weeks later. If ace wrapping is done, choose 6-in. wide or greater, and monitor for constricting bands or pressure skin necrosis over drains. Compression is not so effective in the torso, so a 7-mm diameter suction drain is drawn across the abdomen through the two flank incisions. Thin sheets of foam are placed on the torso, especially within the flanks and where needed to smooth out skin folds. If the foam has a sticky side, multiply incise the edges for an inch or so to minimize shearing that causes blistering.

The garments and foam are removed 5–7 days later. Elastic garments are continued for 3–6 weeks, allowing removal for bathing the second week; sleeping, the third; and inactive periods, the fourth. The drain(s) is/are removed in the first postoperative visit unless there is more than 50 cc of output per day. The patient returns within a week to 10 days for check on seromas or cellulitis. Most swelling is gone by 6 weeks, but final healing may not resolve for 6 months. Unless there is severe deformity, try to postpone revision procedures until then for a more accurate appraisal.



Power-Assisted Lipoplasty

The ease and speed of fat removal can be expedited by the adaptation of a power drill, lasers, or internal therapeutic ultrasound. Power-assisted lipoplasty (PAL) is a reciprocating cannula (powered by gas or electricity) that powers through tissue and vacuums out fat with minimal effort by the surgeon. The author is familiar with the Microaire (www.microaire.com/pal) device with a 2 mm excursion at 4,000 cycles/s. The equipment is highly expensive with only a small number of surgeons using it. It is purported to be a speedier and less injurious to the patient, causing less bruising, swelling, and discomfort, and thereby leading to more rapid recovery.⁴⁴ In a 15-patient pilot study, PAL had a higher per area suction removal capacity compared with traditional SAL with comparable aesthetic results.³⁸ The author finds that the PAL works smoothly with minimal bleeding, but the vibration and noise are annoying.

Laser-Assisted Lipoplasty

Recently a new laser energy device called SmartLipo by Cybnosure, Inc. (Westford, Massachusetts) has been resurrected in the form of 1064 nm ND:Yag delivered by short pulses through a 600 μm optical fiber housed in a microcannula. Ten years ago laser-assisted lipoplasty was found to have no advantage over SAL.³ SmartLipo appears best suited for smaller contour bulges. The cannula is inserted through a small incision and with the guidance of a red helium–neon laser source a liquefied fatty emulsion is created, which may be absorbed or suctioned. A smoother result with better skin contraction is claimed.¹⁶ Direct to consumer marketing of this minimally invasive procedure has been very effective. The author is awaiting conformational studies in the United States.

Ultrasonic-Assisted Lipoplasty

In 20% of the surveyed cases, the most common high-tech energy source for liposuction is ultrasound vibration.⁴ Introduced from Europe in the mid-1990s, UAL is the internal use of probes for cavitation and percussion to emulsify undesirable

fat. The goal is aesthetic recontouring of all accessible regions of the body with maximal skin contraction and rapid recovery. Unquestionably UAL is physically easier than SAL on the surgeon.^{5,35} It virtually glides through the tissue, with particular advantage with more fibrous tissues such as the male breasts, the back, and flanks or when stroking through the scarred subcutaneous tissue of secondary surgery. The vibrating probe appears to bounce off the scar tissue and seeks fat. Less force or thrust by the surgeon may mean a smoother, more consistent result. Vessel disruption with bleeding is rare. Larger volumes may be removed with less effort and no fatigue.

Introduced in 1994, the LySonix,[®] with inline suction has a new 3000 model with a pulsed mode to lower heat generation at the tip. MySonix (Framington, New York), www.misonix.com, produces this reliable machine for Mentor Corporation (Santa Barbara, California). About 9 years ago Sound Surgical Technologies, www.soundsurgical.com, produced the VASER[®], a smaller diameter, multiringed probe that is more efficient at less energy than the LySonix. The sonic energy is increasingly splayed out from one to three rings. The greater the number of rings, the more diffuse is the sonic energy and the less is the thermal injury to the tissues. High resistance to the passage of the probe will prompt the use of a single ring. The VASER[®] mode rapidly cycles the probe on and off, keeping the rod from generating too much heat. The sonic energy is predominantly percussive. Having extra hand pieces are essential because shutdowns occasionally occur with either machine.

The probe is rhythmically passed through the subcutaneous tissue layer by layer. I prefer to start in the subdermal plane and proceed deeper in laminated planes. The tissues are coolest at the start with less chance of damage by the probe tip. The probe should be moved continuously as a motionless probe is not cooled and, hence will generate undesirable focal thermal injury. The entry points are placed in inconspicuous locations and asymmetrically staggered. The helping hand massages the target tissue to the probe, taking care to flatten curvatures of the dermis to avoid end hits. End hits are the thermal damage done to the underside of the skin due to force by the vibrating probe held in place with blanching pressure against the skin.



Evacuation of the emulsion is performed by more rapid-stroke liposuction. Sound Surgical Technologies provide a vented suction system, called Ventx[®], which theoretically causes less damage to the connective tissue. When the threshold vacuum pressure is reached, the cannula releases the tissues, avoiding avulsion of connective tissue. Accordingly, the Ventx[®] cannu-

lae rarely clog. For both UAL and traditional SAL, drains are used for very large-volume removals.

For those experienced in its use, UAL causes less morbidity and more rapid recovery.¹³ The result is smoother than I can routinely achieve with SAL (Figure 10.1). UAL often results in good skin contraction, but that is not predictable. UAL is effective in correction of gynecomastia,

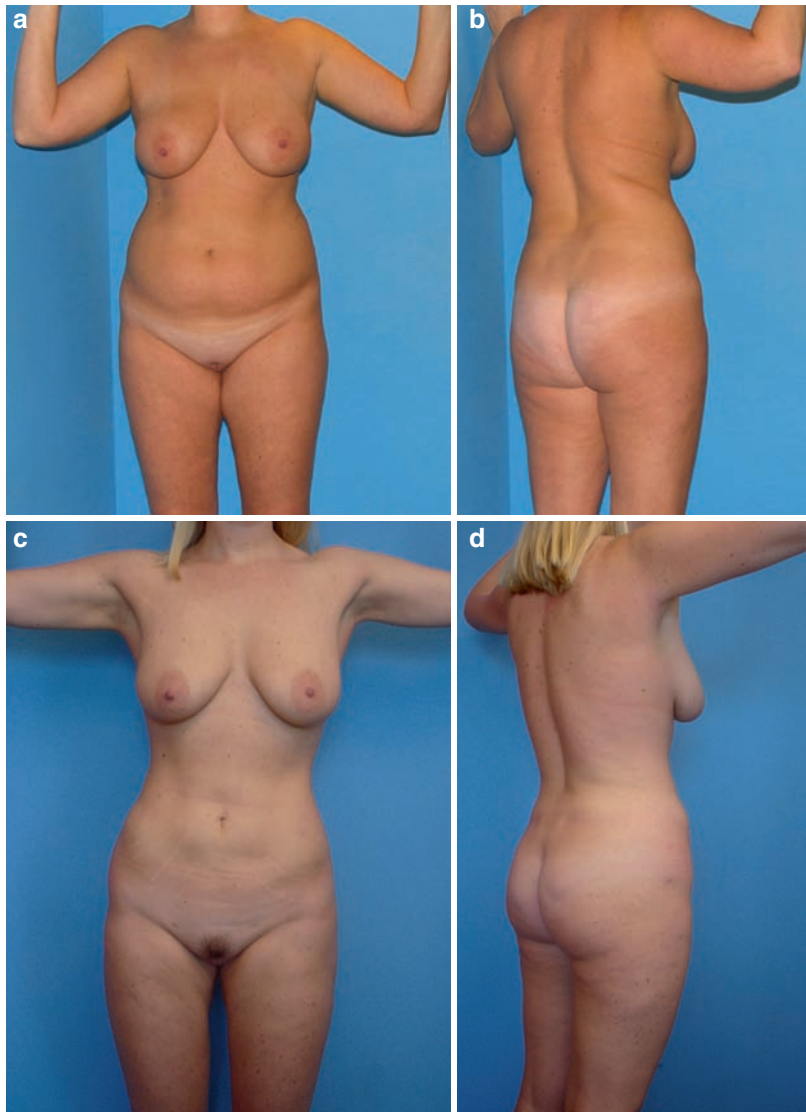


Figure 10.1. Cosmetic UAL. The before (a and b) and 5 months after (c and d) UAL (VASER) of the abdomen, flanks, hips, thighs, arms, and submental region in a 35-year old, weighing 160 lb (BMI 26). She was infused with 3,300 cc of saline with xylocaine and epinephrine. A two-ring probe with VASER was on pulse mode and she was treated for 30 min across the torso and 8 min for each inner and outer thigh. A total of 3,700 cc of fatty emulsion was aspirated via Ventx, of which 2,400 cc was removed from the torso and 800 cc from each thigh.



including mild ptosis. Broad UAL application extending over the anterior to the lateral chest and onto the abdomen with disruption of the inframammary fold leaves a smooth even contour. This bloodless operation is usually followed by a partial glandular excision pull-through removal.²⁰

Clearly, over treatment leaves a leathery appearance due to subcutaneous scar and altered pigmentation. Furthermore, the incisions may be traumatized by torque and hot probe, end hits burn skin, and with resistance being the major end point, prolonged subcutaneous induration can occur.

The initial reports of blistering skin burns, skin loss, prolonged postoperative pain, and high seroma rates hampered the adoption of UAL.^{15,35} The troubling pain may be due to blunt trauma, demyelination injury, or soft tissue scar contracture with entrapment. When neuralgia occurs, resolution of the pain takes months to even years. It is most likely to occur in the anterior thighs and flanks. These problems are avoided by using less power and emulsifying over shorter periods of time. The initial teaching with the inline suction was the end point of energy usage was the desired contour. This led to prolonged use of the probe, and higher power settings were then necessary. The current teaching is to use only as much power as needed to easily move the probe through the tissues. The power should be off when the probe is not moving. The end point of probe passage is when tissue resistance is low. The LySonix inline suction should be seen as a guide to the quality of aspirate only.

Although adipose is most sensitive, the destructive forces of ultrasound energy are not specific for fat. I believe there is a UAL system that comes closer to optimal fat emulsion and that is the Surround Aspirating System developed by El Hassane Tazi of Casablanca, Morocco. The vibrating probe is encased in a firm Teflon-coated cylinder that has a short, enclosed chamber at the end. High suction delivers the fat to this small chamber for rapid fragmentation and removal. Over the past 10 years, Tazi has repeatedly shown excellent fat removal with good skin retraction in large and very large-volume liposuction (Figure 10.2).²¹ We are attempting to introduce this system into the United States.

Radio-frequency-Assisted Lipoplasty

The author is a co-investigator on a recently completed IRB approved trial on the safety and effectiveness of using bipolar radiofrequency internal probe energy for lipolysis tissue healing and skin tightening during lipoplasty of the arms, abdomen and thighs, with attention to technique and skin temperature the rapid removal of fat was followed by up to 30% contracture.

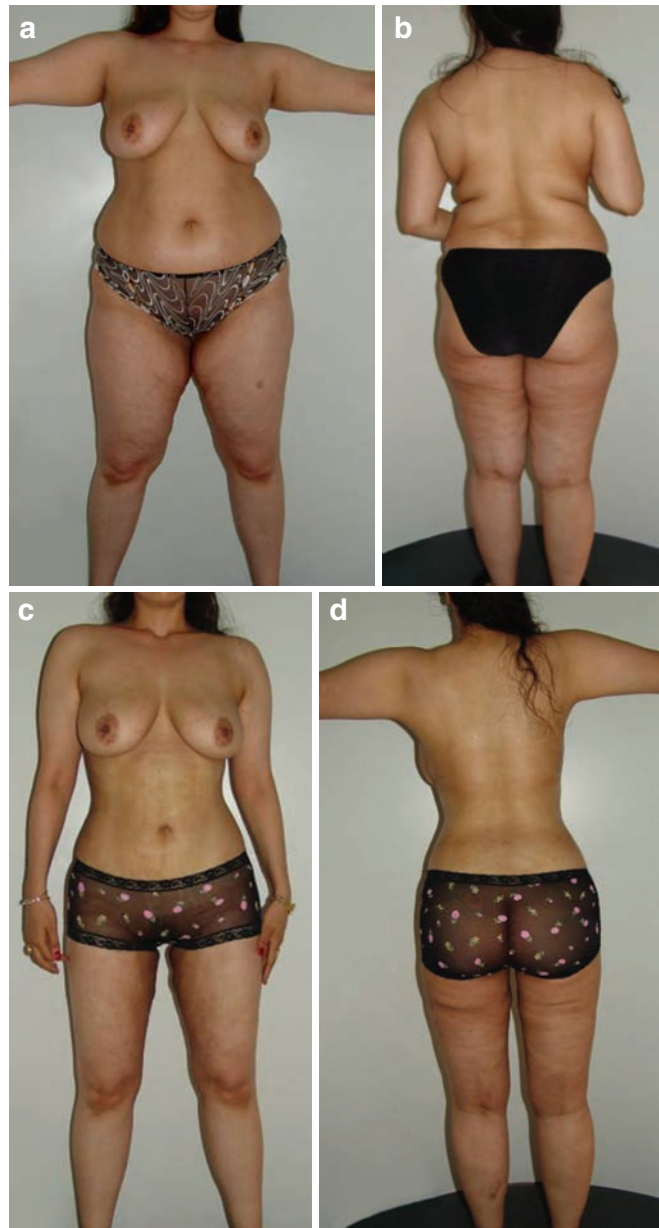
Large-Volume Liposuction

For the many patients with primarily contour excesses and inability to lose weight, an alternative is large-volume liposuction (LVL).^{1,9,11,18,41} Regardless of the technique, LVL for obesity is controversial. Large amounts of fat removal is hours of trauma to the body. As mentioned, intraoperative and immediate postoperative care consider major fluid and electrolyte shifts and concerns of lidocaine and epinephrine toxicity.^{41,42} Retained damaged tissue and bleeding may be a source for prolonged drainage and rare serious infection. Damage to connective tissue and neurovasculature reduction may prolong postoperative swelling and reduce the capacity for the skin to shrink down to the reduced volume. Inadequate contour improvement, sagging skin, and regain of weight are further problems.

Studies conflict on the medical improvement such as reduction of cardiac risk factors, blood pressure, and insulin levels. There are studies showing benefits of liposuction on cardiovascular risk factors, diabetes, and insulin requirements.^{12,14,17,19} Italian researches prospectively studied the medical effects of LVL (average of 3,540 cc) in 30 obese (BMI 30 to 45) and 30 non-obese (under 26) subjects.¹⁹ Their data showed that 2–3 l of fat removal is safe and associated with improvement of some metabolic (insulin resistance) and inflammatory (cytokines and CRP) markers, which are indicators of cardiovascular risk. In fact, a predominant part of the literature shows that LVL improved cardiac risk and vascular inflammatory markers, along with beneficial effects on reduced insulin resistance and vascular inflammation.¹² This health



Figure 10.2. Large-volume liposuction as performed by Dr. Hassane Tazi with SAS/UAL. Preoperative (a and b) and postoperative (c and d) views after 17.5 l removal of fat.



improvement was due to reduced adipocyte reduction of adipokines such as Interleukin-6 and tumor necrosis factor alpha and increased production of anti-inflammatory adiponectin and interleukin-10. They suggest that plastic surgery should be incorporated into a multifaceted program of lifestyle changes for the obese for both contouring and health.¹²

A group from St. Louis reported in the *New England Journal of Medicine* no change in insulin action or risk factors for coronary heart disease in 15 women 3 months after lipoplasty of approximately 9.5 kg of fat from the subcutaneous tissues.²⁹ Patients who went on to lose further weight were eliminated from the study. Clearly, when suction of bulging fat encourages



an improved lifestyle with weight loss, there is an overall health benefit.

Body Contouring and Liposuction

Patients seeking generalized liposuction should be considered for excisional techniques if there is excess skin. Loose skin after weight loss and/or aging will sag further after liposuction. Excisional body contouring surgery improves body contours first by removing excess skin and closing tightly. Second, adipose is selectively left behind, transferred as a flap or removed by liposuction. With increasing presentation of overweight patients for body contouring, combining liposuction with body contouring has become more prevalent. Liposuction maybe performed in a neighboring region or within the advanced body contouring flap. Preservation of blood supply is critical to the safe healing of liposuctioned flaps, which are usually closed under considerable tension. Blood supply is preserved by minimal undermining of flaps and least traumatic fat suctioning.

Lockwood advanced the mid torso ideal of a contoured lateral trunk and inguinal region with a deep waist concavity, convexity of the hypogastrium, concavity of the epigastrium, and a valley between the rectus muscle bulges, with a vertically oriented umbilicus.³² He advocated limited undermining during his high lateral tension abdominoplasty. After the abdominoplasty flap is closed, then liposuction is performed in the epigastrium. A remarkable flattening of the bulging tissue occurred. Other leading plastic surgeons have also advocated liposuction in conjunction with full abdominoplasty^{10,23,33,36,40} (Figure 10.3).

Cardenas–Camarena declared his large-volume torso liposuction (defined as > 1,500 ml, mean of 4.3 kg) and extensive abdominoplasty (mean pannus resections of 1.3 kg) as safe and effective⁸ (<http://online5.hsls.pitt.edu:5551/gw2/ovidweb.cgi - 79#79>). Complications included seromas in three patients, a dehiscence, and one distal flap necrosis.

In 2001, Brazilian plastic surgeons emphasized abdominoplasty without surgical undermining.³⁷ Instead, flap mobility is enhanced by discontinuous undermining provided by liposuction. French

plastic surgeons have advanced excision site profound liposuction as a means to best preserve deep subcutaneous tissue lymphatic channels, thereby reducing the seromas and lymphocele formation during abdominoplasty, brachioplasty, and vertical medial thighplasty.^{31,34}

Over the past 4 years, I have adopted these principles of lipoabdominoplasty with minimal undermining of flaps, maximal preservation of underlying connective tissue, and vascularity throughout all body contouring operations. The results are most dramatic in the overweight patient. On the other hand comes a point at which the adiposity is too excessive to allow for combined therapy. At that extreme, the region is tensely swollen with fat and has no discernable laxity. In those patients, UAL may be all that is necessary or just the first stage of contour correction.

Rohrich is a proponent of concomitant, moderate-volume liposuction with abdominoplasty.³⁶ His group averages 4l of UAL (up to 8,450 cc) of the upper lateral flank, lower back, and upper buttocks, hips and medial thighs, and entire abdomen during his central body lift, circumferential body contouring in 151 patients. He reports high patient satisfaction, excellent results, and a low rate of complications: three major (2%) (two deep vein thrombosis and 1 PE) and 32 minor (21.1%). Surgical revision was required in eight patients (5.3%).³⁶

In fact, Lockwood believed there is a safety factor in discontinuous undermining of the abdominal flap by means of liposuction. He felt it was almost as efficacious as direct undermining with the advantage of improved blood supply³². The ultimate test of this approach is the Brazilian lipoabdominoplasty³⁷. All undermining and fat removal are by liposuction, and only skin is excised. Others have reported that the combination of multiple trunk excisional procedures with liposuction do not have a greater number of complications than isolated abdominoplasty³⁶; however, obese patients have significantly increased morbidity regardless of the number of procedures.¹⁰

Cardenas–Camarena combined abdominoplasty and circumferential liposuction in 310 women patients during a 7-year period, yielding excellent body contouring in a single surgical procedure. There were less than 25% complications even in mostly overweight women.⁷ Gentle manipulation of the tissues prevents cutaneous compromise.

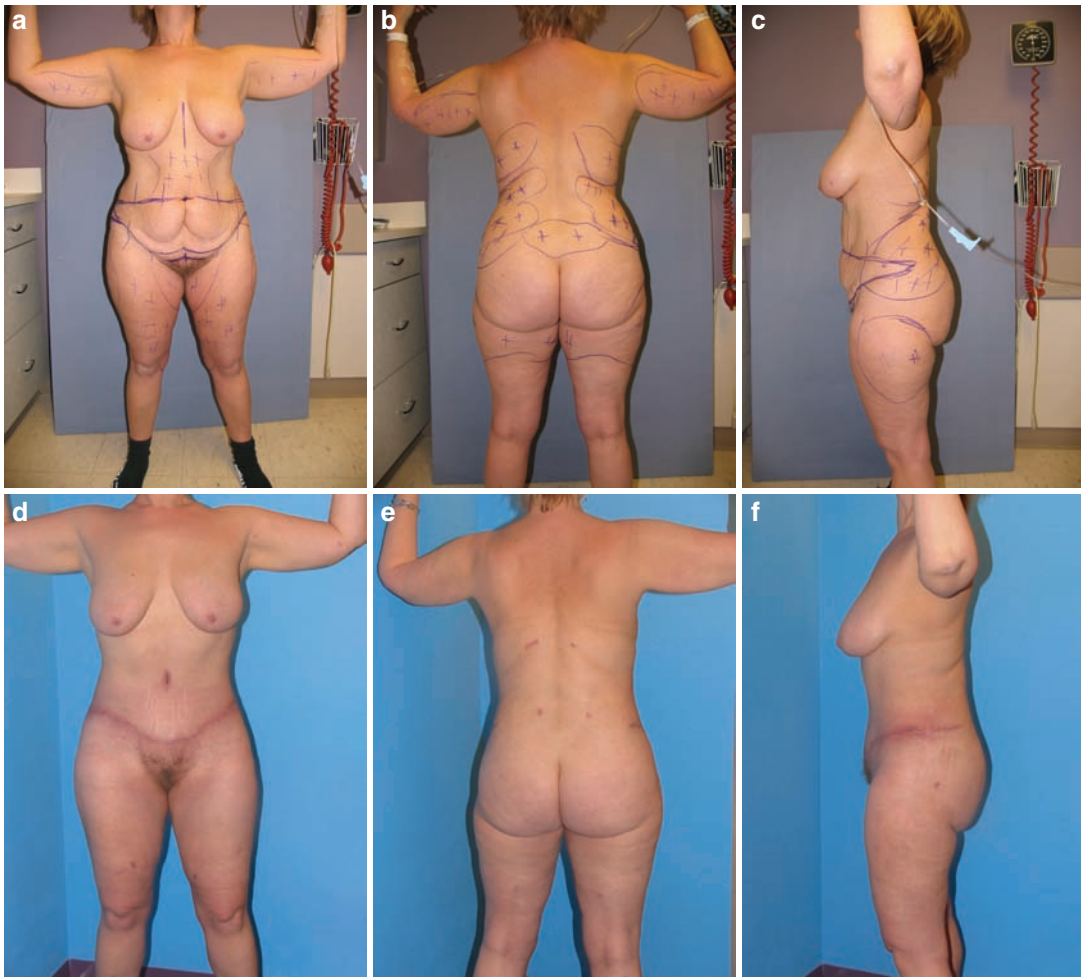

Figure 10.3. Combining body contouring with UAL. The before (**a, b,** and **c**) and 1 month (**d, e,** and **f**) after UAL (VASER) of the flanks, abdomen, and flanks with an extended abdominoplasty in a 44-year old, 148-lb woman.

I agree with this author's conclusion that the combination should be used not as a means to lose weight but as a surgical procedure that improves the body contour in patients with differing degrees of obesity.

References

1. Albin R, de Campo T. Large-volume liposuction in 181 patients. *Aesth Plast Surg.* 1999;23:5–15.
2. Ali Eed. Mega-liposuction: Analysis of 1520 patients. *Aesth Plast Surg.* 1999;23:16–19.
3. Apfelberg DB. Results of multicentered study of laser-assisted liposuction. *Clin Plast Surg.* 1996;23:713–717.
4. ASAPS American Society for Aesthetic Plastic Surgeons. 2006 National Plastic Surgery Statistics. www.surgery.org/press/statistic-2006.php. Accessed 28 December 2007.
5. Beckenstein MS, Grotting JC. Ultrasound-assisted lipectomy using the solid probe: A retrospective review of 100 consecutive cases. *Plast Reconstr Surg.* 2000;105:2175–2181.
6. Brown SA, Lipschitz AH, Kenkel JM, et al. Pharmacokinetics and safety of epinephrine use in liposuction. *Plast Reconstr Surg.* 2004;114:756–763.
7. Cardenas-Camarena L. Aesthetic surgery of the thoracoabdominal area combining abdominoplasty and circumferential lipoplasty: 7 years' experience. *Plast Reconstr Surg.* 2005;116:881–890.
8. Cardenas-Camarena L, Gonzales LE. Large-volume liposuction and extensive abdominoplasty: A feasible alternative for improving body shape. *Plast Reconstr Surg.* 1998;102:1698–1709.



LIPOSUCTION TECHNIQUES

9. Commons GW, Halperin B, Chang C. Large volume liposuction: A review of 631 consecutive cases over 12 years. *Plast Reconstr Surg.* 2001;108:1764–1770.
10. Dillerud E. Abdominoplasty combined with suction lipoplasty: A study of complications, revisions, and risk factors in 487 cases. *Ann Plast Surg.* 1990;25:333–340.
11. D'Andrea F, Grella R, Rizzo MR, et al. Changing the metabolic profile by large-volume liposuction: A clinical study conducted with 123 obese women. *Aesth Plast Surg.* 2005;229:472–478.
12. Esposito K, Giugliano G, Scuderi N, Giugliano D. Role of adipokines in the obesity-inflammation relationship: The effect of fat removal. *Plast Recon Surg.* 2006;118:1048–1055.
13. Fodor FB. Personal experience with ultrasonic-assisted lipoplasty: A pilot study comparing ultrasound-assisted lipoplasty with traditional lipoplasty. 2004;113:1852–1853.
14. Giese SY, Bulan EJ, Commons GW, Spear SL, Yanovski JA. Improvements in cardiovascular risk profile with large-volume liposuction: A pilot study. *Plast Reconstr Surg.* 2008;108:510–519.
15. Gingrass MK. Lipoplasty complications and their prevention. *Clin Plast Surg.* 1999;26:341–354.
16. Goldman A. Submental Nd:Yag laser-assisted liposuction laser for laser lipolysis. *Lasers Surg Med.* 2006;38:181–184.
17. Hardy KJ, Gill GV, Bryson JR. Severe insulin-induced lipohypertrophy successfully treated by Liposuction. *Diabetes Care.* 1993;16:929–930.
18. Greco RJ. Massive liposuction in the moderately obese patient: A preliminary study. *Aesth Surg J.* 1997;17:87–90.
19. Giugliano G, Nicoletti G, Grella E, et al. Effect of liposuction on insulin resistance and vascular inflammatory markers in obese women. *Brit. J. Plast Surg.* 2004;57:190–194.
20. Hammond DC, Arnold JF, Simon AM, Capraro PA, Rohrich RJ, Ha RY. Combined use of ultrasonic liposuction with the pull-through technique for the treatment of gynecomastia. *Plast Reconstr Surg.* 2003;112:891–895.
21. Hurwitz DJ. Surround aspiration system for ultrasonic assisted lipoplasty presentation in the hot topics seminar of the annual meeting of the American Society of Aesthetic Plastic Surgeons, Orlando, FL, April 21, 2006.
22. Illouz YG. Body contouring by lipolysis: A 5 year experience with over 3000 cases. *Plast Reconstr Surg.* 1983;72:591–602.
23. Illouz YG. A new safe and aesthetic approach to suction abdominoplasty. *Aesth Plast Surg.* 1992;16:237–244.
24. Iverson RE, Lynch DJ. Practice advisory on liposuction. *Plast Reconstr Surg.* 2004;113:1478–1490.
25. Karmo F, Milan M, Stein S, Heinsimer J, et al. Blood loss in major lipoplasty procedures with the tumescent technique. *Ann Plast Surg.* 1998;18:30–35.
26. Kenkel JM, Lipschitz AH, Luby M, et al. Hemodynamic physiology and thermoregulation in liposuction. *Plast Reconstr Surg.* 2004;114:503–513.
27. Kenkel JM, Lipschitz AH, Shepherd G, et al. Pharmacokinetics and safety of lidocaine and monoethylglycineylidide in liposuction: A microdialysis study. *Plast Reconstr Surg.* 2004;114:516–524.
28. Klein JA. The tumescent technique: Anesthesia and modified liposuction technique. *Dermatol Clin.* 1990;8:425–431.
29. Klein S, Fontana L, Young VL, et al. Absence of an effect of liposuction on insulin action and risk factors for coronary heart disease. *N Engl J Med.* 2004;350:2549–2557.
30. Lee C. Guidelines for ensuring safety in large-volume liposuction. *Sem Plast Surg.* 2002;16(2):153–156.
31. Le Louarn C, Pascal JF. The concentric medial thigh lift. *Aesth Plast Surg.* 2004;28:20–23.
32. Lockwood TE. High lateral tension abdominoplasty with superficial fascial system suspension. *Plast Reconstr Surg.* 1994;96:603–611.
33. Matarasso A. Liposuction as an adjunct to full abdominoplasty. *Plast Reconstr Surg.* 1995;95:829–834.
34. Pascal JF, Le Louarn C. Brachioplasty. *Aesth Plast Surg.* 2005;29(5):423–429.
35. Rohrich RJ, Beran S, Kenkel J. *Ultrasound Assisted Liposuction.* St. Louis, MO: Quality Medical; 1999.
36. Rohrich RJ, Gosman AA, Conrad MH, Coleman J. Simplifying circumferential body contouring: The central body lift evolution. *Plast Reconstr Surg.* 2006;118:525–535.
37. Saldanha OR, de Souza Pinto EB, WN Matos, et al. Lipoabdominoplasty without undermining. *Aesth Surg J.* 2001;21:518–526.
38. Scuderi N, Tenna S, Spalvieri C, De Gado F. Power-assisted lipoplasty versus traditional suction-assisted lipoplasty: Comparative evaluation and analysis of output power-assisted lipoplasty versus traditional suction-assisted lipoplasty: Comparative evaluation and analysis of output. *Aesth Plast Surg.* 2005;29:49–52.
39. Spring M, Gutowski K. Venous thrombosis in plastic surgery patient: Survey results of plastic surgeons. *Aesth Surg J.* 2006;18:30–35.
40. Teimourian B, Gotkin RH. Contouring of the midtrunk in overweight patients. *Aesth Plast Surg.* 1989;13:145–149.
41. Thomas M, Bhorkar N, D'Silva J, Menon H, Bandekar N. Anesthesia considerations in large-volume lipoplasty. *Aesth Surg J.* 2007;27:607–611.
42. Trott SA, Beran SJ, Rohrich RJ, Kenkel JM, Adams WP Jr, Klein KW. Safety considerations in and fluid resuscitation in liposuction: An analysis of 53 consecutive patients. *Plast Reconstr Surg.* 1998;102:2220–2229.
43. Weniger FG, Calvert JW, Newton ED. Liposuction of the legs and ankles: A review of the literature. *Plast Reconstr Surg.* 2004;113:1771–1785.
44. Young VL. Plastic surgery educational foundation educational committee power-assisted lipoplasty. *Plast Reconstr Surg.* 2001;108:1429–1432.
45. Young VL, Watson ME. Prevention of perioperative hypothermia in plastic surgery. *Aesth Surg J.* 2006; 26:551–557.